

INVESTIGATION OF HEPATOCELLULAR CARCINOMA AND FOCAL NODULAR HYPERPLASIA ON TRIPHASIC COMPUTED TOMOGRAPHY

Laiba Tariq^{*1}, Tahira Batool², Faiza Haq Nawaz³, Areej Faisal⁴, Muhammad Riaz⁵

^{*1}Postgraduate Student, MS Medical Imaging Technology (Allied Health Sciences)
Department of Radiological Sciences and Medical Imaging Technology, the Superior
University, Lahore, Pakistan

²Assistant Professor, Faculty of Allied Health Sciences, Superior University Lahore, Pakistan

^{3,4}Postgraduate Student, MS Diagnostic Ultrasound (Allied Health Sciences)

Department of Radiological Sciences and Medical Imaging Technology, the Superior
University, Lahore, Pakistan

⁵Lecturer, Department of Allied Health Sciences, University of Sargodha, Sargodha, Pakistan

Corresponding Author: ^{*1}laibatariq434@gmail.com

DOI: <https://doi.org/10.5281/zenodo.14729364>

ABSTRACT

Objective: To observe the focal nodular hyperplasia images will be evaluated and contrasted with the hepatocellular carcinoma images in each phase of the triphasic CT scan, the other objective was to evaluate the diagnostic precision of triphasic CT for differentiating FNH from HCC through vascular and anatomical features that distinguish FNH from HCC and finding clinical usefulness for accurate and timely diagnoses with triphasic CT scan results.

Study design: It was a cross-sectional study design.

Place and duration of study: The study was conducted at THQ Hospital Sadiqabad, Pakistan from August to December 2024.

Material and Methods: By adopting cross-sectional study design Thirty-five individuals with FNH and thirty-five with HCC were among the seventy patients studied. In order to find diagnostic signals specific to each illness, the study assessed delayed phase imaging, arterial imaging, and portal venous imaging.

Results: About The results revealed that The majority of instances occurred in patients aged 61–80 years (48.57%), followed by 41–60 years (40%), with 57.14% of patients being male and 42.85% being female in the FNH study. Among the complaints were numerous symptoms (40%) and stomach discomfort (25.71%), and 42.85% had a history of declining liver function. During the arterial phase, imaging revealed hyperdense lesions with regular borders in 28.57% of cases and irregular borders in 65.71%. No washout or central scars were found in the delayed phase, and 80% of patients had hypodense lesions during the venous phase. The frequency of HCC peaked in the age range of 41–60 years (45.71%), with 51.42% of men and 48.57% of women affected. Jaundice (5.71%) and stomach discomfort (54.28%) were among the symptoms, while 28.57% had no previous medical history. In the arterial phase, imaging showed hyperdense lesions with irregular boundaries in 82.85% of cases, whereas in the venous phase, it showed isodense lesions in 97.14% of cases. Unfortunately, there was a washout period and also lack of core scarring

The Research of Medical Science Review

across all cases. Peak incidence of HCC is noted in males and females aged 41-60 years: of 45.71 percent, 51.42 percent were men and 48.57 were women. The only symptoms which make up the majority of metastasizing cases are jaundice (5.71%) and abdominal pain (54.28%), while 28.57% of those affected have no past medical history. Imaging of the arterial phase revealed hyperdense lesions with irregular boundaries in 82.85% of the cases, whereas for the venous phase isodense lesions were detected in 97.14%. In each case, a washout phase and absence of core scarring were recorded.

Conclusion: *We concluded that Triphasic CT is important in differentiating between focal nodular hyperplasia (FNH) and hepatocellular carcinoma (HCC). An analysis of the specific image features delivered by artery and portal venous delay phases had led us to locate special diagnostic determinants bearing on each disease. The assessment of diagnostic accuracy with significant specificity and sensitivity between the two liver lesions proved reliable for triphasic CT and was informative for the clinical practice.*

Keywords: *Focal nodular hyperplasia (FNH), hepatocellular carcinoma (HCC), arterial phase, venous phase, delayed phase Triphasic CT scan, age, women, men*

INTRODUCTION

HCC and FNH are the two main liver lesions, whereas their pathophysiology differs and can present with similar clinical manifestations. Hepatocellular carcinoma, by far the most common primary malignant tumor of the liver, develops especially in chronically diseased livers, has a very high morbidity rate matched by its mortality, and strongly favors early diagnosis with high accuracy.

HCC, the most commonly conceived primary cancer of liver, grows very often in chronically diseased livers, had very high morbidity associated with it, and quite often resulted in mortality. HCC therefore calls for very early and accurate diagnosis. FNH is, however, a non-neoplastic lesion which rarely becomes serious or symptomatic and usually occurs in liver tissue that is otherwise completely normal. For practical and effective clinical decision-making, triphasic CT imaging-an arterial, portal venous, and delayed phase-is crucial with regard to vascular characteristics between HCC and FNH. Overlapping findings can make diagnosis harder, even with such excellent specificity and sensitivity, indicating a need for further research on additional distinguishing markers for improvement in parameters...(1)

Important structural alterations in HCC include of:

Tumor Formation and Nodule Development: In the liver, HCC usually manifests as one or more nodules. Although they may invade adjacent tissue, these nodules vary in size and are typically hard and well-defined. Depending on their aggressiveness and spread, some tumours form in numerous areas (multifocal) whereas others manifest as a single mass (unifocal).(2)

Loss of Normal Liver Architecture: The liver's typical hexagonal lobular pattern is upset by HCC, which causes irregular tumour cells to replace the liver's functioning cells. Hepatocytes, sinusoids, and central veins lose their ordered arrangement, which affects blood flow and liver function in the afflicted regions.(3)

Vascular Changes and Angiogenesis: Angiogenesis, the creation of new blood vessels to sustain the tumor's fast growth, is a characteristic of HCC. These arteries can cause chaotic blood flow because they frequently have aberrant branching and uneven walls. Because of this increased blood supply, HCC tumours usually show hypervascularity in the arterial phase of imaging. (3)

Capsule Formation: HCC tumors frequently form a fibrous capsule, a barrier of connective tissue that encloses the tumour mass. Because this capsule is often lacking, tumour cells can enter the surrounding tissues. Well-differentiated HCCs are more likely to form capsules, whereas poorly differentiated tumours are often more invasive.(3)

Cellular Atypia: Cellular atypia, such as larger nuclei, abnormal cell shapes, and elevated nuclear-to-cytoplasmic ratios, are seen in HCC cells under a microscope. Because of their hepatocytic origin, these cells may generate bile pigments and frequently feature large nucleoli and enhanced mitotic figures.

Trabecular and Pseudoglandular Patterns: As HCC develops, tumour cells may produce aberrant gland-like forms called pseudoglandular structures or thickened trabeculae, which are cords of cells. These patterns

The Research of Medical Science Review

differentiate malignant hepatocytes from benign cells and are suggestive of the aggressive, disordered cell proliferation observed in HCC.

Fibrosis and Cirrhosis: In cirrhotic livers, where fibrosis (scarring) impairs the normal liver structure, HCC commonly develops. Cirrhosis-related fibrosis and nodular regeneration can further deform the liver's structural integrity by fostering the formation of tumors.(3)

Necrosis and Hemorrhage: Regions of necrosis (cell death) within HCC tumours can occur when the mass's centre becomes larger than its blood supply. Additionally, there may be bleeding into the abdominal cavity or into the tumour, which might lead to serious consequences. Because they alter the liver's appearance on imaging and add to the tumor's aggressive character, these structural alterations are crucial to the development and detection of HCC. A benign liver lesion known as focal nodular hyperplasia (FNH) is typically asymptomatic and is found by accident, frequently during imaging tests for other illnesses. More often seen in young adult women, it is the second most common benign liver tumour after hepatic haemangioma. FNH does not have the potential to develop into cancer, in contrast to malignant liver lesions, and usually doesn't need treatment until it causes symptoms. A crucial characteristic in identifying FNH is the hyperplastic mass of normal liver cells (hepatocytes) that surrounds the lesion with a central stellate scar.

The core scar's distinctive appearance on imaging is a result of the presence of fibrous tissue, aberrant blood arteries, and bile ducts. To differentiate it from malignant liver tumours like HCC, FNH exhibits homogenous enhancement in the arterial phase on triphasic CT or MRI, whereas the central scar may show up as a hypodense region that increases in the delayed phase.(4), A crucial characteristic in identifying FNH is the hyperplastic mass of normal liver cells (hepatocytes) that surrounds the lesion with a central stellate scar. The core scar's distinctive appearance on imaging is a result of the presence of fibrous tissue, aberrant blood arteries, and bile ducts. In contrast with malignant liver tumors such as HCC, FNH demonstrates homogeneous enhancement in the arterial phase on triphasic CT(4). FNH is thus marked by a well-organized but abnormal expansion of the normal liver cells and composition of tissue parts. The following structural alterations are seen in FNH:

Central Stellate Scar: A central scar is one of the characteristic features of FNH radiating outward in a stellate or star-shaped pattern. This scar is formed with thick fibrous tissue and has aberrant blood vessels. Because it improved frequently on the delayed phase, it is an identifying feature on imaging.(5)

Fibrous Septa and Radiating Fibrous Bands: Through fibrous bands or septa, the primary scar in FNH grows into the neighboring tissue. Such bands are what give the tumor its distinctly lobulated shape-by dividing it into nodules.(5)

Abnormal Vascular Architecture: Because of aberrant arteries and veins inside the lesion, FNH is linked to altered blood flow patterns. The neovascularity commonly observed in malignant tumors is not present in these vessels, which are frequently big, tortuous, and thick-walled. The lesion's quick and uniform amplification during the arterial phase of imaging is facilitated by the increased blood flow to it.(6)

Hyperplastic Hepatocytes: Hyperplastic hepatocytes, which resemble normal liver cells but proliferate haphazardly around the primary scar, make up the lesion. These cells set FNH apart from liver tumors since they don't exhibit any atypia or malignancy. Overall liver function is usually not affected by the lesion since the hepatocytes in FNH continue to operate normally.(7)(6)

Bile Duct Proliferation: The core scar and spreading fibrous bands frequently include tiny, asymmetrical bile ducts. Unlike the organised bile duct systems present in other areas of the liver, these bile ducts are often scant and defective.

No Capsule Formation: FNH lacks the fibrous capsule that envelops several other liver tumors. Rather, it seamlessly integrates with the adjacent liver parenchyma, further setting it apart from cancerous growths. **Lobulated Structure with Nodular Hyperplasia:** Clusters of hyperplastic hepatocytes and fibrous tissue give FNH lesions their nodular appearance and frequent multilobulation. This nodular structure helps explain why it appears diverse on imaging. FNH is often regarded as a stable, benign lesion with little chance of complications or cancer. Because they produce a unique pattern on imaging, especially CT and MRI scans, these structural characteristics are crucial for diagnosis.(8)

The Research of Medical Science Review

Materials & Methods

Thirty-five individuals with FNH and thirty-five with HCC were among the seventy patients were included in the study. Informed consent was obtained by consent form THQ hospital Sadiqabad Pakistan from August to December 2024. Patients were clearly informed about the aims and objectives of the study and their rights. If the patient agreed to participate then was asked to sign the consent form. The consent form was provided in both Urdu and English languages. If the patient was unable to read then the consent form was read loudly and verbal consent was taken. By adopting cross-sectional study design well-structured questionnaire was developed for the collection of data. The questionnaire contained information regarding demographics such as age,gender,diagnosis symptoms such as abdominal Pain, weight lose, fatigue, nausea, vomit, jaundice, ascites and fever and clinical history such as chronic liver disease, cirrhosis, hepatitis B&C, alcohol abuse, diabetes and recent worsening of liver functions etc.The collected data was entered into a computer spread sheet for analysis in the SPSS version.21. We applied descriptive statistics to find frequencies.

Results

In the current study below bar graph(Figure 1) shows that, out of 70 patients, Thirteen (42.85%) of the 35 patients that were included in our study based on FNH analysis were female, while twenty (57.14%) were male, while Based on HCC analysis, a total of 35 patients were included in our study; 18 (51.42%) of these patients were male, and 17 (48.57%) were female, as shown in the accompanying table.

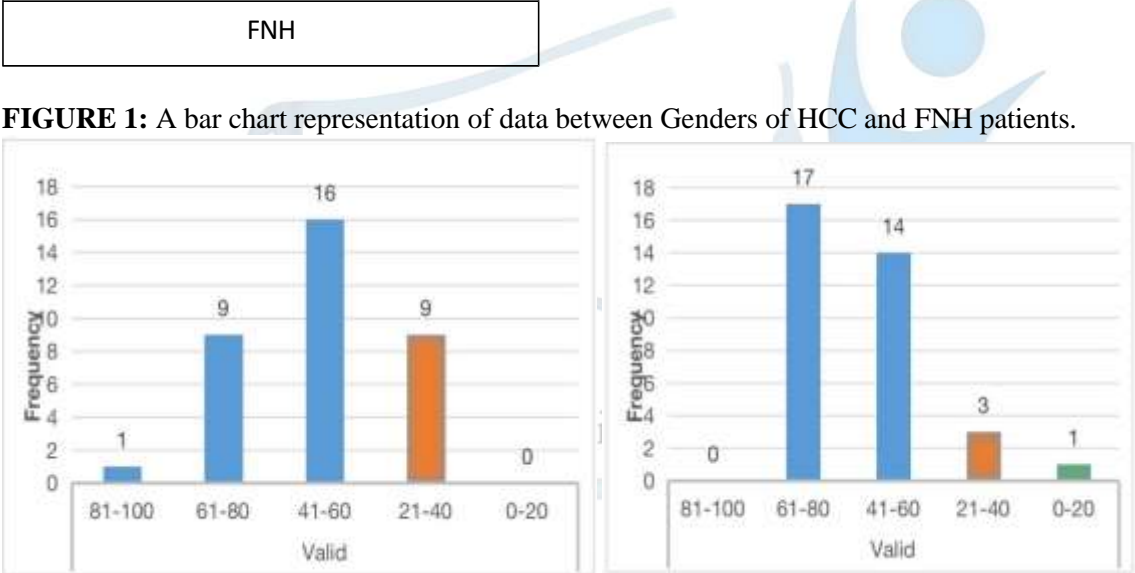
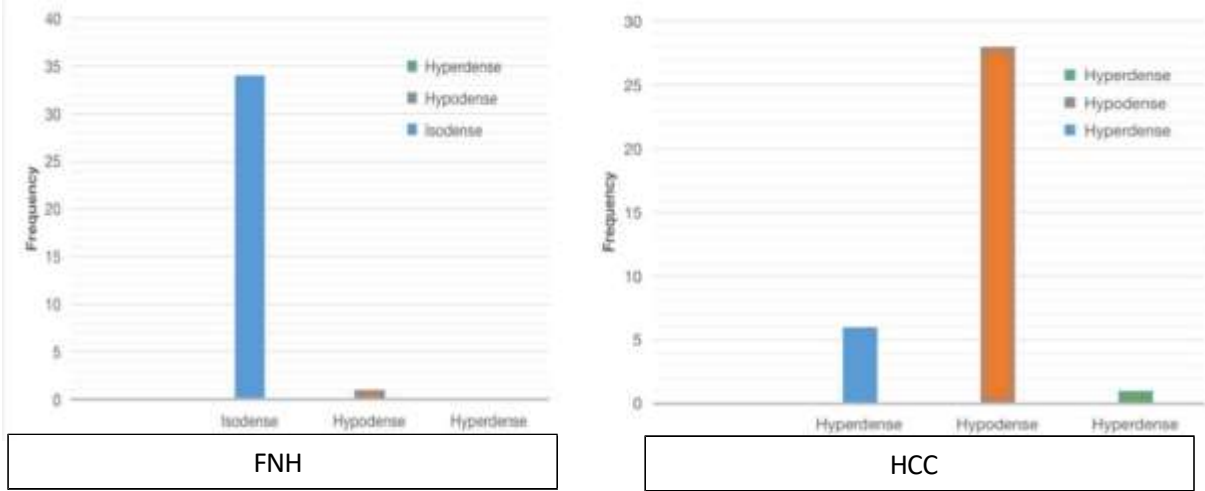


FIGURE 1: A bar chart representation of data between Genders of HCC and FNH patients.

A total of 35 patients were included in our study based on FNH analysis, as shown in the following table. On CT scan examination, FNH was higher in patients who were between the ages of 61 and 80 (17, or 48.57%), 14 (or 40%), and 3 (8.57%) who were between the ages of 21 and 40, and 1 (2.85%) who were between the ages of 0 and 20 while based on HCC analysis, we included 35 patients in total. HCC was higher in 16 patients (45.71%) who were between the ages of 41 and 60, 9 patients (25.71%) who were between the ages of 21 and 40, 9 patients (25.71%) who were between the ages of 61 and 80, and 1 patient (2.85%) who was between the ages of 81 and 100 on CT scan examination.

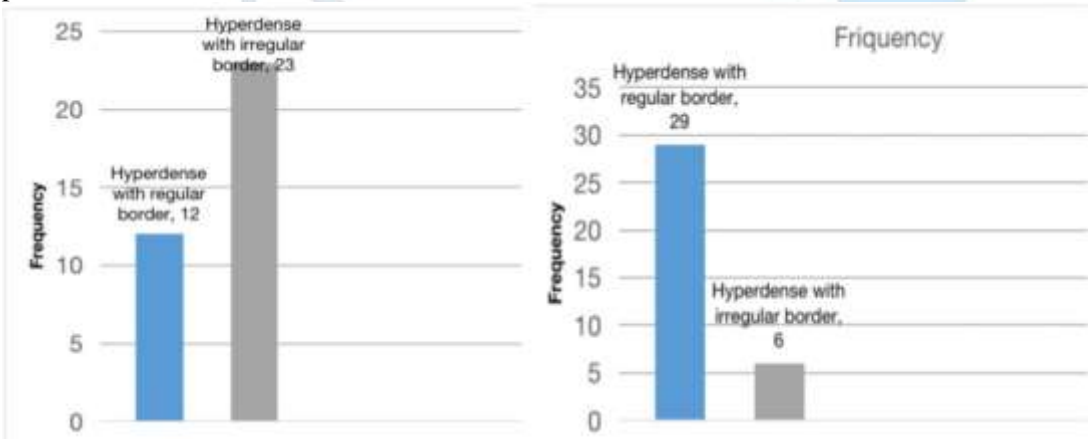
The Research of Medical Science Review

FIGURE 2: A bar chart representation of data between age ranges among FNH patients and HCC Patients.



This bar graph below (FIGURE 3) shows 12 patients (28.57%) had hyperdense with regular borders, whereas 23 patients (65.71%) had hyperdense with irregular borders during the arterial phase in FNH patients while 35 patients , 29 (82.8%) of the patients had hyperdense with regular borders, whereas 6 (17.14%) had hyperdense with irregular borders during the arterial phase in HCC phase.

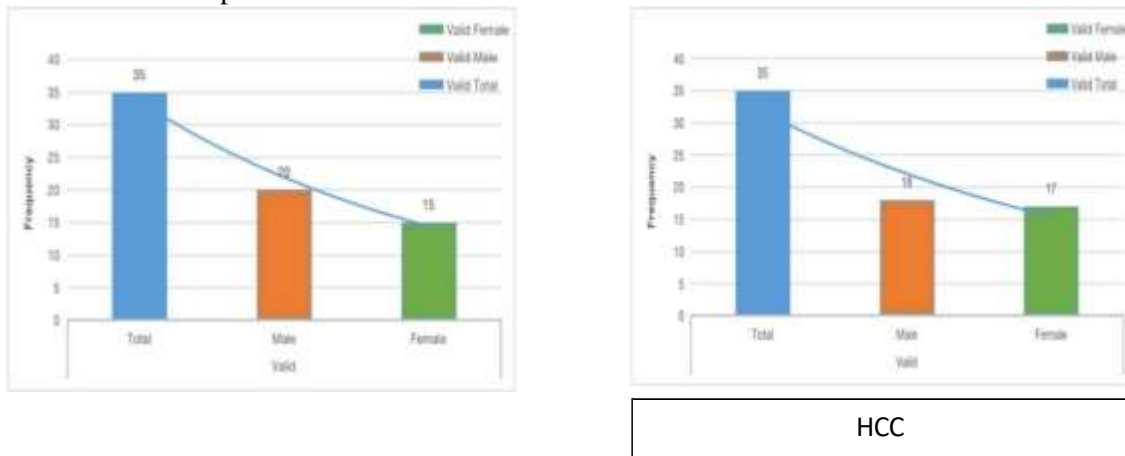
FIGURE 3: A bar chart representation of data between Hyperdense with regular border, Hypodense with regular border, Hyperdense with irregular border, Hypodense with irregular border in arterial phase of HCC patients.



The bar graph (FIGURE 4) bellow shows that out of the 35 FNH patients in our sample, 1 (2.85%) had hyperdense substance, 28 (80%) had hypodense substance, and 6 (17.14%) had hyperdense substance in the venous phase while out of the 35 HCC patients in our sample, 1 (2.85%) had hypodense and 34 (97.14%) had isodense in the venous phase.

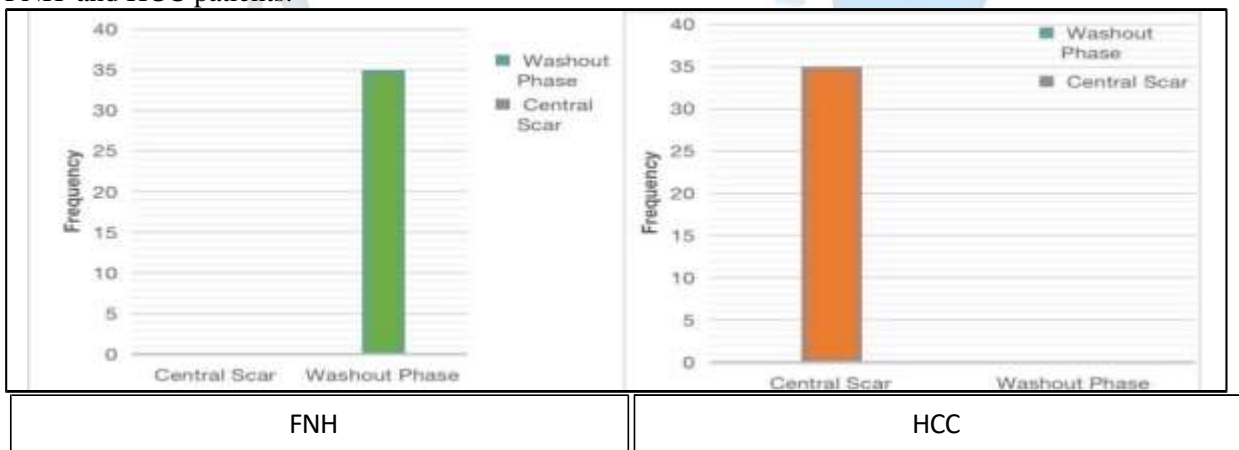
The Research of Medical Science Review

FIGURE 4: A bar chart representation of data between hyperdense, hypodense and isodense in venous phase of FNH and HCC patients.



The below bar graph (FIGURE 5) shows that 35 (100%) of the patients had a washout phase, and patients with FNH in the delayed phase showed no signs of a central scar. Patients with HCC showed no signs of a washout phase, whereas 35 patients (100%) had central scarring and a delayed phase while patients with HCC showed no signs of a washout phase, whereas 35 patients (100%) had central scarring and a delayed phase.

FIGURE 5: A bar chart representation of data between washout phase and central scar in delayed phase of FNH and HCC patients.



Discussion

In this study we found that Out of these, 35 persons are patients diagnosed with HCC: 15 of them are males (42.8%) while 20 others are females (57.14%). The rest of the 35 had been diagnosed with FNH, of which 17 were female (48.57%) and 18 were male (51.42%). They included pretriphasic CT scanning clinical evaluation, patient symptom and history review. Throughout the three phases, the imaging results showed different patterns for FNH and HCC, providing important information for distinction. Consistent with observations in the literature, HCC showed typical arterial-phase hyperenhancement followed by fast washout in the portal venous and delayed phases. On the other hand, FNH showed uniform amplification and a central scar that was apparent in the delayed phase, which is consistent with recognised diagnostic characteristics (9). Hyperdense lesions with regular borders were seen in 12 cases (28.57%) of Focal Nodular Hyperplasia in the arterial phase, while irregular borders were noted in 23 cases (65.71%). Conversely, in the arterial phase of Hepatocellular Carcinoma, 29 patients showed hyperdense lesions with regular borders (82.8%), whereas 6 presented with irregular ones (17.14%). According to previous studies, the imaging properties of HCC can differ; on unenhanced images, they are frequently hypodense or isodense in

The Research of Medical Science Review

comparison to the liver, but they may seem hyperdense in situations with underlying fatty liver.(10) None of the individuals affected by hepatocellular carcinoma (HCC) presented with washout finding during the delayed phase of this trial; however, all patients who had focal nodular hyperplasia (FNH) showed 35 patients involved with it as 100%.Furthermore, 35 patients (100%) with FNH displayed central scarring in the delayed phase, while patients with HCC did not exhibit any central scarring. These results are consistent with earlier research, confirming the diagnostic value of triphasic CT scans in distinguishing between FNH and HCC. According to Osman et al. (2021), a central scar is a defining characteristic in the diagnosis of FNH.(10)

The hyperdense lesions in 6 (that is, 17.14%) study subjects present during the venous phase consisted of 35 individuals; they had hypodense lesions in 28 (80%) and hyperdense lesions in only 1 (2.85%). In addition, isodense lesions were seen in 34 of the individuals (97.14%). Hypodense lesions were present in 1 of the subjects (2.85%). These results support earlier research and emphasize the diagnostic use of CT imaging in the diagnosis of hepatocellular carcinoma (HCC). According to previous studies the state of the liver can have a substantial impact on the imaging features of HCC. In contrast to normal liver parenchyma, HCCs may look hypodense or isodense on unenhanced imaging. They could, however, have hyperdense characteristics if they have a fatty liver. Important diagnostic indicators for HCC also include characteristics including the presence of fat, vascular invasion, an internal mosaic pattern, and interval growth of 50% or more within six months(2). We recruited 35 patients with hepatocellular carcinoma (HCC) and 35 patients with focal nodular hyperplasia (FNH) based on the clinical history they presented. Of the 35 HCC patients, 9 (25.71%) share a similar patient clinical history with 11 (31.42%) of FNH patients who on inquiry had a history of Hepatitis B and C, in contrast, 2 (5.71%) patients had cirrhosis, 5 (14.28%) reported signs of having recently impaired liver function, and 1 (2.85%) presented with chronic liver disease. These findings underscore the importance of clinical history in the differentiation between FNH and HCC. Our results support these correlations, emphasising how crucial it is to screen for HBV and HCV in patients with liver lesions in order to enhance early diagnosis and results.(11)

Conclusion:

We concluded that Triphasic CT is important in differentiating between focal nodular hyperplasia (FNH) and hepatocellular carcinoma (HCC). An analysis of the specific image features delivered by artery and portal venous delay phases had led us to locate special diagnostic determinants bearing on each disease. The assessment of diagnostic accuracy with significant specificity and sensitivity between the two liver lesions proved reliable for triphasic CT and was informative for the clinical practice.

Limitations and Future Directions:

This study will recognize the disclosed limitations of imaging, including an emphasis on correlating with histology, and potential obstacles where atypical instances might be diagnosed through imaging overlaps between HCC and FNH. In summary, this study will comprehensively study triphasic CT for liver lesion discrimination under all possible aspects with a focus on both technical aspects of the imaging modality as well as the clinical relevance of an accurate diagnosis for FNH and HCC. It is anticipated that the results would improve hepatology diagnostic procedures and offer insightful information about liver imaging.

Conflicts of Interest:

We declare that we have no conflicts of interest regarding this research project. This includes financial interests, consulting arrangements, affiliations, or any involvement with organizations that could potentially bias our research.

The Research of Medical Science Review

REFERENCES:

- Nie, P., Yang, G., Guo, J., Chen, J., Li, X., Ji, Q., Wu, J., Cui, J., & Xu, W. (2020). A CT-based radiomics nomogram for differentiation of focal nodular hyperplasia from hepatocellular carcinoma in the non-cirrhotic liver. *Cancer Imaging*, 2020.
- Chon YE, Park SY, Hong HP, Son D, Lee J, Yoon E, et al. Hepatocellular carcinoma incidence is decreasing in Korea but increasing in the very elderly. *Clin Mol Hepatol*. 2023
- Liu Z, Jiang Y, Yuan H, Fang Q, Cai N, Suo C, et al. The trends in incidence of primary liver cancer caused by specific etiologies: Results from the Global Burden of Disease Study 2016 and implications for liver cancer prevention. *J Hepatol*. 2019
- Li, W., Li, R., Zhao, X., Lin, X., Yu, Y., Zhang, J., Chen, K., Chai, W., & Yan, F. (2021). Differentiation of hepatocellular carcinoma from hepatic hemangioma and focal nodular hyperplasia using computed tomographic spectral imaging. *Journal of Clinical and Translational Hepatology*
- Rumgay H., Shield K., Charvat H., Ferrari P., Sornpaisarn B., Obot I., Islami F., Lemmens V.E.P.P., Rehm J., Soerjomataram I. Global burden of cancer in 2020 attributable to alcohol consumption: A population-based study. *Lancet Oncol*. 2021
- Marrero J.A., Kulik L.M., Sirlin C.B., Zhu A.X., Finn R.S., Abecassis M.M., Roberts L.R., Heimbach J.K. Diagnosis, Staging, and Management of Hepatocellular Carcinoma: 2018 Practice Guidance by the American Association for the Study of Liver Diseases. *Hepatology*. 2018
- Galle P.R., Forner A., Llovet J.M., Mazzaferro V., Piscaglia F., Raoul J.-L., Schirmacher P., Vilgrain V. EASL Clinical Practice Guidelines: Management of hepatocellular carcinoma. *J. Hepatol*. 2018
- Omata M., Cheng A.-L., Kokudo N., Kudo M., Lee J.M., Jia J., Tateishi R., Han K.-H., Chawla Y.K., Shiina S., et al. Asia-Pacific clinical practice guidelines on the management of hepatocellular carcinoma: A 2017 update. *Hepatol. Int*. 2017
- Gaillard, F., Walizai, T., Kogan, J., et al. (2024). Focal nodular hyperplasia
- Lv, X., Ye, G., Zhang, X., et al. (2017). p16 Methylation was associated with the development, age, hepatic viruses infection of hepatocellular carcinoma, and p16 expression had a poor survival: A systematic meta-analysis
- Alberts CJ, Clifford GM, Georges D, Negro F, Lesi OA, Hutin YJ, et al. Worldwide prevalence of hepatitis B virus and hepatitis C virus among patients with cirrhosis at country, region, and global levels: a systematic review. *Lancet Gastroenterol Hepatol*. 2022

Research of Medical Science Review