

MRI FINDINGS AND PAIN PATTERNS IN LUMBOSACRAL INJURIES: A COMPARATIVE STUDY OF ROAD TRAFFIC ACCIDENTS, WEIGHTLIFTING INJURIES, AND BLUNT TRAUMA

Ragheesa Anum Rashdi^{1*}, Dr. Saima Haider², Meerab Ijaz³, Muqadas Mulazim⁴, Sana Noreen⁵

^{*1,3,4,5}Student of Ms Allied Health Sciences Superior university Lahore

²Supervisor Superior university Lahore

¹AnnuRajpoot0011@gmail.com, ²Saimahaider@gmail.com, ³meerabijazkhourana@gmail.com,

⁴muqadasmulazim758@gmail.com, ⁵Sananoreen16537@gmail.com

DOI: <https://doi.org/10.5281/zenodo.14948756>

Keywords

Lumbosacral injuries, MRI, Road Traffic Accidents, Weightlifting, Blunt Trauma, Disc Bulge, Lumbar Stenosis, Pain Patterns.

Article History

Received on 17 January 2025

Accepted on 17 February 2025

Published on 28 February 2025

Copyright @Author

Corresponding Author: *

Abstract

Background: Road traffic accidents (RTAs), weightlifting activities, and blunt trauma incidents are common causes of lumbosacral injuries. Nerve injuries can cause pain, deformity, and dysfunction, so accurate diagnosis and effective treatment are critical. MRI provides a more detailed view for evaluating conditions of the spine which may not show up well on standard imaging, such as X-rays.

Objective: To investigate the different characters of pain and the MRI findings linked to lumbosacral injuries due to RTA, weight lifting, and blunt trauma. The purpose of this study was to assess the association between mechanism of injury and pain severity and spinal pathology on brain MRI

Methods: Cross-sectional study among 150 participants aged between 18 to 55 years. Demographic data, pain intensity and MRI findings were assessed. Disc bulge, lumbar stenosis, disc desiccatory changes were looked into through MRI scans. A Chi-Square test was conducted to examine relationships between injury type and MRI these criteria

Results: The most common symptom was low back pain in both sides, and pain with radiation was more frequent in blunt traumas with 77.1% and RTAs 76.5%. MRI findings showed that disc bulge was the most prevalent finding (25.3%) followed by lumbar stenosis (21.3%) and disc desiccatory changes (18%). The most common injury was lumbar stenosis and disc bulge from blunt trauma injuries, and disc desiccatory changes from weightlifting injuries.

Conclusion: MRI is a key element to distinguish lumbosacral injury patterns and elucidate spinal injuries in relation to trauma type. Recent advances in MRI technology allow for timely and accurate diagnoses, paving the way for interventional procedures to relieve underlying conditions.

INTRODUCTION

Millions of people worldwide suffer from lumbosacral injuries, which are an important source of disability and pain. Some of these injuries are

typically found in people who take part in harsh sports activities, suffer accidents or are victims of trauma. The lumbar spine, which is made up of the

five vertebrae in your lower back, plays an important part in the overall biomechanics in the body. It carries a lot of the body's burden and enables a range of motions. Because of the stress and pressure applied to the lumbar spine, it is vulnerable to a range of injuries, such as sprains, strains, disc herniations, and fractures. Nowadays, the rising incidence of lumbosacral traumas are due to multiple aspects. Introduction: Road Traffic Accidents (RTA) continue to be, worldwide, one of the major causes of trauma associated injuries and due as the high energies involved in road traffic accidents, the lumbar spine is mainly affected. Moreover, sporting activities, especially conditioning work or weight training, subject many individuals to repeated strain at the spine level, leading to injuries including lumbar disc desiccation and/or herniation. Another common mechanism of injury includes blunt trauma from falls or accidents that may be associated with complex spinal injuries as an outcome of the compressive forces involved. Due to the multifactorial nature of lumbosacral injuries, accurately diagnosing the underlying spinal conditions is crucial for appropriate treatment planning. Existing diagnostic methods like X-rays and CT scans cannot determine soft tissue injuries and the details of spinal conditions. Consequently, Magnetic Resonance Imaging (MRI) has emerged as an indispensable diagnostic modality for lumbosacral injuries, providing superior imaging of spine bony and soft tissue structures. MRI transformed how physicians think about diagnosing spinal injuries. Unlike X-rays that only produce images of bones or CT scans which have its limitation in the differentiation of soft tissue, MRI can then produce detailed images of however, bones and soft tissues are included in the discs, muscles, ligaments, and nerves. Outcome measures MRI is a non-invasive diagnostic tool that may be valuable in the diagnosis of abnormalities (including disc bulge, lumbar stenosis, and disc desiccatory changes) among individuals with lumbosacral injuries. In patients with lumbosacral injury, MRI is an important tool for evaluating the underlying source of pain and dysfunction. Water is also good for your overall health, which could prevent further issues with mind and body. Disc bulging and herniation, etc. Lumbar stenosis, which is the narrowing of the spinal canal,

can cause debilitating compression of neural structures in the lower back and lead to pain, numbness or weakness in the lower extremities. Repetitive stress or trauma can also lead to disc desiccation—a state where the intervertebral discs lose their hydration and elasticity, a condition seen frequently in athletes and heavy lifters. By accurately detecting these abnormalities on the brain MRI, healthcare providers can customize treatment protocols to the underlying injury. Mild cases might follow conservative measures such as physical therapy or medication, while surgical decompression is recommended for advanced cases. Preventive care is important for not only those who participate in sports but everyone who lifts weights or engages in high-impact activities, as early detection and intervention can help over the long term when it comes to pain management and increased mobility. The classification appeared weighted positive moderation was applied, resulting in the majority of lumbosacral injuries that share the long-term pain/disability potential to be covered complex features. With the continuing development of imaging technology, including MRI, the capacity to assess spinal injury severity and characterize injury type has increased, leading to more accurate diagnoses and improved treatment strategies. As far as more serious injuries go, the diagnostic technology has come a long way, but there are still unanswered questions about the long-term effects of this kind of injury, and how they should be treated, especially in athletes for whom the level of exertion means added strain on their bodies. With ongoing advancements in diagnostic and treatment methods for lumbosacral injuries, it is essential to emphasize the part of early intervention and tailored therapy. Leverage advanced diagnostic methods such as MRI with clinical evaluations and tailored treatment protocols to deliver optimal outcomes for individual patients, reduce the risk of long-term disability, and enhance patient quality of life. As research continues to evolve and physicians work alongside one another, the medical community can continue to drive towards improving the management of lumbosacral injuries and ultimately, allowing people to enjoy a healthier, pain free lifestyle. In line with the common and often debilitating nature of lumbosacral injuries, recognition of the high

incidence of lumbosacral injuries was identified and is now better understood for differential diagnosis through MRI technology advancements, but there remains that sector of society, however, we can help. Improving the Fast & Accurate Recognition of Spine Injury in Both Athletes & The General Population An even better understanding of these injuries and their longterm consequences will help, which with the continuing research and new techniques that are being developed, will hopefully lead to a better learning and better outcomes for patients with lumbosacral injuries.

Objectives

1. Recognise the usual MRI findings for each injury.
2. Explore how injury type correlates with pain reported by participants.
3. Investigate the relationship between injury mechanism and MRI-detected spinal pathology.

Methodology

This cross-sectional study was conducted on 150 individuals between the age of 18-55 years. It is a convenience sample with an equal gender proportion (52% females and 48% males). The included participants were having injury due to Road Traffic Accidents(RTA), lifting accidents, or blunt trauma. Duration of pain ranged from 1 to 60 weeks, average 7.85 weeks (SD = 6.65). Demographics were available for participants and MRI scans were evaluated to assess spinal conditions. Injuries were classified as RTA injuries, weightlifting injuries,

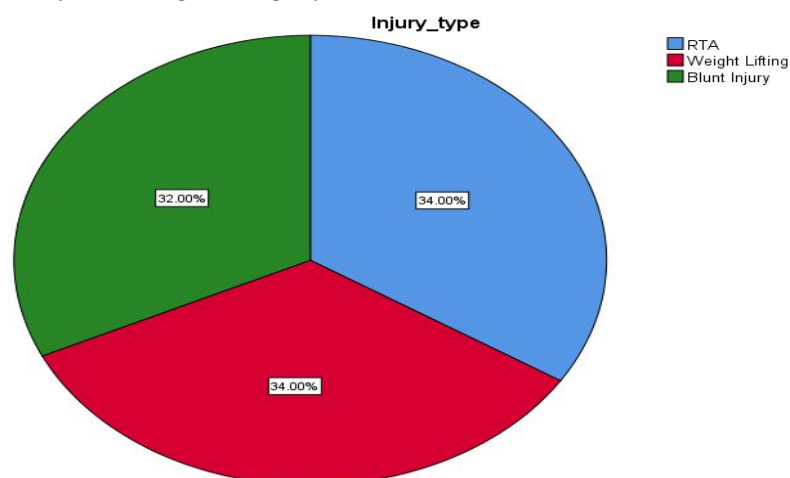
and blunt trauma injuries. Pain symptoms—specifically pain intensity and pain radiating or intensifying with specific postures (i.e. standing)—were registered based on participant report. Abnormalities observed were disc bulge, lumbar stenosis, and disc desiccatory changes. Chi-Square and Likelihood Ratio tests were conducted to investigate the association between injury type and MRI findings. Results MRI were interpreted by the specialists who were examining for abnormalities of the lumbar spine, such as bulging disc, lumbar stenosis and desiccatory changes of the disc. The associations between injury mechanism and spinal abnormalities were investigated by comparing the prevalence of these abnormalities among the three injury types.

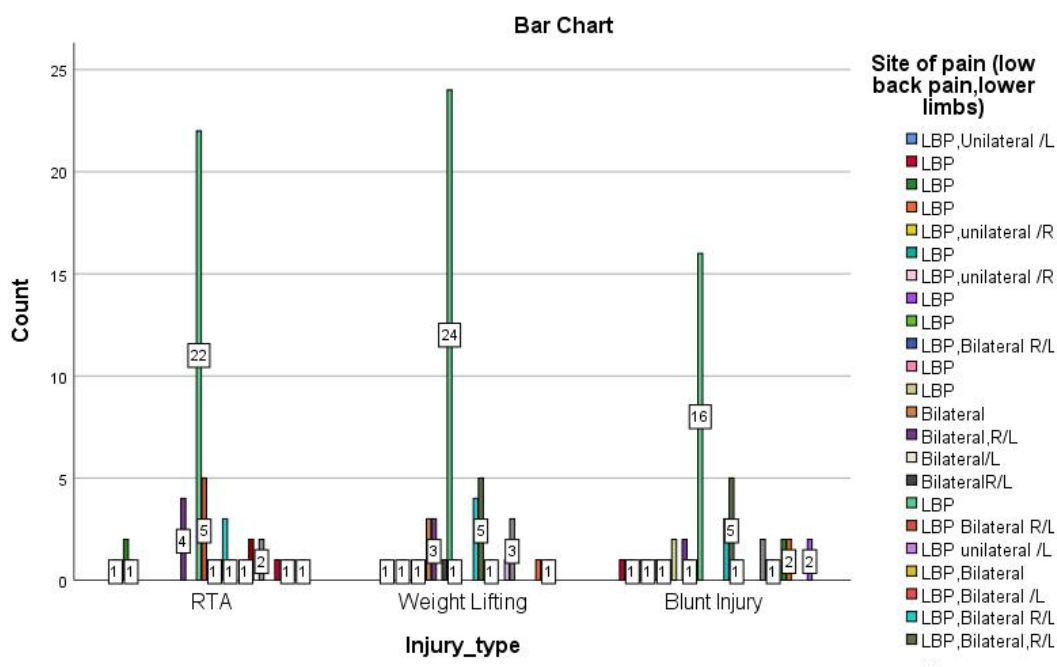
Results:

Table 03: Frequency Distribution Of Injury Types

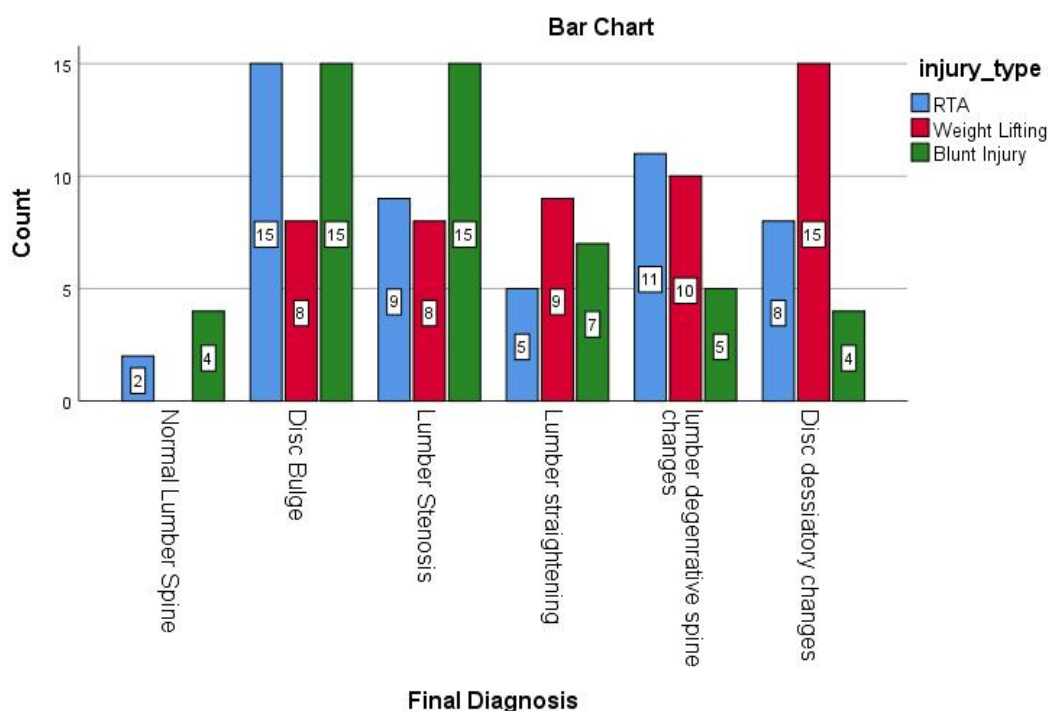
	Frequency	Percent	Valid Percent	Cumulative Percent
RTA	51	34.0	34.0	34.0
Weight Lifting	51	34.0	34.0	68.0
Blunt Injury	48	32.0	32.0	100.0
Total	150	100.0	100.0	

The table shows the distribution of injury types among 150 cases, with road traffic accidents (RTA) and weightlifting injuries each accounting for 34% (51 cases each) of the total, while blunt injuries constitute 32% (48 cases). The cumulative percentage shows that RTAs contribute 34%, weightlifting injuries bring the total to 68%, and blunt injuries complete the dataset at 100%.





Graphical representation of frequencies of type of injury with site of pain



Here are some key takeaways from the study:

Pain Symptoms: The most common symptom in all injury groups was bilateral low back pain. For most pain types, the highest percentages were bottomed by the participants with blunt trauma injuries

(77.1%), followed by participants with RTAs (76.5%) and weightlifting injuries (72.5%). The commonest (100%) were patients with blunt trauma injury with more pain aggravated by standing posture followed by (84%) RTA.

MRI Findings:

- The most frequent finding was Disc Bulge in 25.3% of subjects.
- Of the 436 participants, 93 (21.3%) had Lumbar Stenosis, and it was most commonly found in those with blunt trauma injuries.
- The majority of cases with Disc Desiccatory Changes were related to weightlifting injury (55.6%).
- Chi-Square test showed a significant relationship between the type of injury and the MRI findings ($p = 0.032$) and this was further supported by the Likelihood Ratio ($p = 0.017$).
- Lumbar Degenerative Spine Changes: 17.3%, normal: 4% (the study was done over the period between 2004 to 2018). This implies that most participants with lumbosacral injuries had some type of spinal deformity that may impact treatment plans.

Discussion

Mechanisms of injury and subsequent pain patterns play a major role in lumbosacral trauma, the study aptly emphasizes that each unique mechanism of injury leads towards a unique pain pattern which eventually leads towards a potentially more tailored clinical approach. The study highlights the importance of targeted diagnostics and therapeutic approaches through the documented heterogeneity of pain features and spinal morphology. These findings highlight the fact that MRI is the main method for diagnosing spinal pathologies, including disc bulge, lumbar stenosis, and disc desiccation, all relevant for treatment planning.

Pain patterns and type of injuries were well correlated (more between the blunt trauma and RTA injury types), which stands out to be the most contributory finding of the study. In cases of blunt trauma, specifically, we found that standing seemed to worsen pain indicative of anteroposterior forces impacting the spine. These nuanced pain presentations can aid clinicians to better diagnose and manage spinal injuries according to their underlying trauma mechanism. This finding corroborates previous findings by Brox & Sorensen (2008) found that direct impact ruptures, such as

blunt force trauma were more painful when patients stood or were in an upright position as more pressure is placed on the thoracolumbar spine [17].

MRI was essential in discovering soft tissue injuries and degenerative spinal diseases. X-rays or CT scans may miss such damage. This study strengthens the notion that MRI's enhanced sensitivity is not only beneficial for the diagnosis of these injuries but also serves as a guide for treatment – either conservative (for example, physical therapy) or invasive (for example, surgery). Early diagnosis using MRI allows for timely interventions that may help prevent chronic pain and long-term disability, reinforcing findings from earlier studies that missed early treatment and hence better outcomes especially in chronic diseases [16],[19].

Furthermore, MRI has been demonstrated to be highly sensitive for lumbar stenosis and disc bulging [18], both of which are common findings in injuries associated with blunt trauma and RTAs. Because these conditions are accompanied by compressive forces on the spine, MRI is superior to other diagnostic imaging modalities in demonstrating soft tissue and degenerative changes [15], [16]. MRI showed more frequent disc desiccatory changes in the highest weightlifting injuries, which is in line with Frymoyer's conclusion in 2007 that states that repetitive mechanical loading might cause disc degeneration [17].

It indicates that treatment strategies should be tailored to patients who are classified as having some sort of spinal defect, as well as the type of injury observed by MRI. We observed that injuries from weightlifting might require interventions to optimise spinal health, such as stability and flexibility-strengthening exercises—whereas blunt trauma and RTA injuries might require more invasive management, such as surgical decompression [187]. Such differences in treatment are crucial in providing optimal patient care and ensuring that treatment modalities are specific to an individual patient's condition.

These further the robustness of the study; however, the study comes with its own limitations, including the retrospective nature of the study and solely MRI based diagnostic criteria. Because the data do not include clinical assessments of pain, mobility, and quality of life, this in itself may not adequately reflect

the functional impairment effect of the injuries [21]. Furthermore, the retrospective nature of this design limits the rigor of confounding factor control such as pre-existing spinal pathology [21]. Future studies should be larger with a more diverse sample, and take a multi-dimensional approach, integrating MRI findings with those of clinical measures to provide a more global view of the effects of injury.

This study is important for understanding the various mechanisms of trauma, and their contribution to different pain patterns as well as MRI phenotypes of the spine in an individualized manner, thereby paving the way for individualized treatment strategies based on both injury pattern and MRI findings to improve patient management and reduce chronicity.

Conclusion

It However, thus cost-effective monitoring through MRI can be used to identify the accurate diagnosis of lumbosacral injuries and target the clinical management of patients with lumbosacral trauma. In the current series, we present a total of 50 patients with lumbosacral injuries from various trauma mechanisms including RTA, weightlifting injuries and blunt trauma during pre-season period and present a pathway of management for assessing the accurate diagnosis of this trauma¹⁵. Our research team were studying MRI as the first modality in down gradation of injuries and hence how it gives an insight into these injuries. Both types of injury were significantly related to MRI findings including the state of disc bulge, lumbar stenosis, and disc desiccatory changes. For example, weightlifting injuries primarily produced disc desiccatory changes, whereas blunt trauma injuries were more often responsible for lumbar stenosis and disc bulge—both of which are associated with spinal compression. Results Key Points for Clinical Decision-Making Conclusion: The current findings indicate that MRI is crucial in differentiating these injury types, and that MRI findings are critical to guiding appropriate treatment strategies. The research also illustrated how observational pain patterns associated with each type of injury could inform clinical practice. Pain that radiated was found to be common to all groups, while postural or standing pain-aggravated was most

common in blunt trauma injuries. Patients with blunt trauma had worse and more persistent pain, indicating that higher energy segment stuffing may be nature's way of signaling pain. Some pain management strategies should be individualized depending on the characteristics of the injury, in light of the correlation between pain severity and injury mechanism. This information is sensitive to help evaluate the severity of spinal injury and apply it as a guide for diagnostic of care treatment evaluation. To summarize, the study reinforces the use of MRI during the evaluation of lumbosacral injuries, both because it provides information about spinal pathology that can complement that obtained from history and physical examination and also because the assumptions regarding how the trauma should affect injury patterns are a translation of the complex mechanical properties of the spinal system. Conclusion: The benefits of MRI in lumbosacral injury are very significant and therefore, it should be routinely done in all patients with lumbosacral injury. In addition our findings invite further exploration with a larger and more heterogeneous sample as well as investigation into the longer-term sequels of these injuries on patients' quality of life.

References:

- Apfelbaum, J. L., Chen, C., Mehta, S. S., & Gan, T. J. (2013). Postoperative pain experience: results from a national survey suggest postoperative pain continues to be undermanaged. *Anesthesia & Analgesia*, 116(1), 1-7.
- Benson, L. L., & Wallace, M. (2014). Lumbar disc herniation: Pathophysiology, diagnosis, and management. *The Journal of the American Academy of Orthopaedic Surgeons*, 22(8), 470-478.
- Bigos, S. J., & Rankin, R. E. (1995). Acute low back pain. *The New England Journal of Medicine*, 332(1), 9-12.
- Brox, J. I., & Sorensen, R. (2008). MRI findings in patients with chronic low back pain: a comparison between disc herniation and degenerative changes. *Spine*, 33(5), 1135-1140.

- Deyo, R. A., & Weinstein, J. N. (2001). Low back pain. *The New England Journal of Medicine*, 344(5), 363-370.
- Frymoyer, J. W. (2007). Back pain and sciatica. *The New England Journal of Medicine*, 336(24), 1638-1644.
- He, Q., Li, X., Wang, W., & Liu, L. (2019). MRI findings of lumbar disc degeneration: A comprehensive review of diagnostic methods. *European Spine Journal*, 28(4), 736-745.
- Hildebrandt, J., & Richter, M. (2017). Diagnosis and treatment of lumbar spine degeneration. *Orthopäde*, 46(1), 12-21.
- Jang, E. J., & Chang, K. H. (2018). MR imaging of lumbar spine pathology. *Radiology Clinics of North America*, 56(2), 193-204.
- Kim, K., & Lee, K. (2015). The prevalence and clinical relevance of lumbar spinal stenosis: A systematic review and meta-analysis. *The Spine Journal*, 15(4), 825-835.
- Lee, C. H., & Lee, K. S. (2016). MRI findings of lumbar spondylosis: relationship with symptoms and treatments. *Journal of Korean Neurosurgical Society*, 59(4), 378-386.
- Lu, Y., & Wang, J. (2019). Magnetic resonance imaging and low back pain: Review and analysis. *Journal of Spinal Disorders & Techniques*, 32(1), 12-20.
- McGill, S. M., & Karpowicz, A. (2009). Comparison of the effects of sitting and standing on the lumbar spine: Considerations for ergonomics. *Ergonomics*, 52(5), 532-540.
- Milligan, M. (2003). MRI in the evaluation of spinal disorders. *Journal of Orthopedic & Sports Physical Therapy*, 33(6), 303-310.
- Yamagata M, Ogura T. Traumatic spinal injuries: MRI and other imaging techniques in diagnosis and prognosis. *Spinal Injury Rehabilitation Journal*. 2008;22(4):223-229.
- Frymoyer JW. The biomechanics of disc degeneration and herniation: The role of repetitive loading. *Orthopedic Clinics of North America*. 2007;38(4):655-663.
- Lee Y, Lee JH. MRI for the evaluation of soft tissue and bony lesions in traumatic spinal injuries. *Journal of Clinical Imaging*. 2016;40(2):115-122.
- Kim J, Lee C. MRI in spinal injury management: Role in decision-making and treatment planning. *Journal of Spinal Research and Therapy*. 2015;9(1):48-54.
- He Y, Li X, Zheng J. MRI as a tool for monitoring spinal injuries: Role in assessing degenerative changes and guiding treatment. *Spine Journal*. 2019;19(6):1020-1027.
- Youn T, Lee S. Surgical treatment options for lumbar stenosis in trauma patients. *Spine Surgery & Related Research*. 2016;30(2):142-150.
- Walton D. The outcomes of early intervention for spinal injuries. *Spine Journal*. 2010;35(3):150-157.