

## COMPARATIVE EVALUATION OF CT ENTEROGRAPHY (CTE) AND MR ENTEROGRAPHY (MRE) IN SMALL BOWEL DISEASE DIAGNOSIS: A PROSPECTIVE STUDY

Muqadas Mulazim<sup>1\*</sup>, Dr. Saima Haider<sup>2</sup>, Ragheesa Anum Rashdi<sup>3</sup>

<sup>\*1,3</sup>Student of Ms Allied Health Sciences Superior University Lahore

<sup>2</sup>Supervisor Superior university Lahore

<sup>1</sup>muqadasmulazim758@gmail.com, <sup>2</sup>Saimahaider@gmail.com, <sup>3</sup>AnnuRajpoot0011@gmail.com

DOI: <https://doi.org/10.5281/zenodo.15021765>

### Keywords

CT enterography, MR enterography, small bowel disease, Crohn's disease, inflammatory bowel diseases, diagnostic imaging, bowel inflammation.

### Article History

Received on 17 January 2025

Accepted on 17 February 2025

Published on 28 February 2025

Copyright @Author

Corresponding Author: \*

### Abstract

**Background:** Timely diagnosis of small bowel diseases, especially the inflammatory bowel diseases (IBDs) such as Crohn's disease, is still essential for effective treatment. Recent advances in non-invasive imaging methods, particularly CT enterography (CTE), and MR enterography (MRE), have become important tools for diagnosis.

**Objective:** To compare the diagnostic accuracy and clinical utility of CTE and MRE in diagnosing small bowel diseases, with particular attention to their sensitivities, specificities, and total diagnostic efficacy.

**Method:** A prospective study was designed including 40 patients who had undergone CTE and MRE. The comparative diagnostic efficacy of human and artificial intelligence modalities were analyzed in the context of the small bowel pathologies, with a focus on inflammation, strictures, and fistulas. Sensitivity, specificity, and predictive values were calculated and compared.

**Result:** MRE and CTE had similar outcomes in detecting small bowel diseases, with the most common findings being inflammation. In contrast, CTE had higher specificity, and MRE had higher sensitivity for identifying mild bowel inflammation. The classic finding of lymphadenopathy was present in 45% of patients but did not add to the diagnostic yield.

**Conclusion:** Both CTE and MRE are useful in evaluating small bowel diseases. CTE holds the edge in specificity, thus are advantageous for structural assessments whereas MRE does better at detecting subtle early inflammatory changes. The preference for imaging technique should be guided by the successful patients, especially in the light of radiation exposure.

### INTRODUCTION

Allocating much of its volume to the small intestine, disorders and diseases of the small bowel, encompassing inflammatory bowel disease (IBD), tumor(s) or infections (among several others), are considerable diagnostic predicaments owing to the anatomy of the small intestine as well as its

versatile functions. The importance of diagnosing these conditions accurately and quickly is vital, for management and treatment purposes. Although valuable for diagnosis, invasive procedures such as endoscopy and biopsy are difficult to perform repeatedly, especially for disease progression.

Therefore, non-invasive imaging modalities, especially CT enterography (CTE) and MR enterography (MRE), have served as the pillar of diagnosing and monitoring small bowel diseases. There are benefits and drawbacks to both CTE and MRE in the assessment of small bowel pathology. CT enterography employs contrast-enhanced computed tomography to image the gastrointestinal tract, producing high-resolution images that can be particularly helpful in evaluating structural changes, including strictures, fistulas, and bowel perforations. CT has, therefore, become a mainstay of acute complication evaluation in those with advanced disease, given its rapid assessment of the full abdomen. CTE, on the other hand, exposes to ionizing radiation, which restricts the utility of this technique for frequent follow-up in younger patients or in patients requiring prolonged monitoring. Such concerns have prompted the wider use of MRE, as it is a safer alternative to radiation and is therefore better suited for pediatric patients and patients requiring multiple assessments over time. Contrast imaging with MR enterography enables assessment of the small bowel with high soft-tissue contrast, allowing detection of subtle inflammatory changes [2]. MRE has proven to be particularly effective in imaging bowel wall thickening, inflammation, and complications from Crohn's disease such as fistulas and abscesses. While MRE does not use radiation, it still has some drawbacks, such as longer scan times, higher costs, and limited availability in specific healthcare settings. Although both modalities have been reported to have similar effectiveness in evaluating small bowel pathology, the differences in CTE and MRE sensitivity, specificity and diagnostic accuracy are still being explored. The few studies that have compared these imaging modalities have had mixed results, largely due to both the clinical setting and the kind of pathology in question. MRE has been reported to be superior in detecting early inflammatory changes, but CTE may be better suited for the evaluation of complex structural abnormalities and acute complications. To this end, the present study provides a systematic comparison of the diagnostic capabilities of CE and MR enterography in small bowel diseases, particularly inflammatory bowel diseases including Crohn's

disease, highlighting the diagnostic superiority of these techniques over others. By comparing their sensitivity, specificity, and overall diagnostic performance collectively, we aspire to help with clinical decision-making and understand which imaging modality might be favored in different clinical contexts. By comparing findings from imaging methods in a population of patients with suspected small bowel disorders, we aim to add to the emerging literature focused on optimizing non-invasive diagnostic strategies and enhancing patient care.

## Objective:

This study has the goal of:

1. Objective To relatively analyze the diagnostic performance of CT enterography (CTE) and MR enterography (MRE) in the detection of small bowel diseases.
2. Calculate the sensitivity, specificity, and positive and negative predictive values for both modalities.

## Methodology:

This A total of 40 patients (19 female, 21 male; mean age 58 years; range 26–93 years) who underwent CT enterography (CTE) and MR enterography (MRE) as part of their clinical workup for documented or suspected small bowel disease were studied. Patient Population: Twenty-six (65%) male and 14 (35%) female patients with a median age of 31.45 years (ranging from 14 to 64 years). Selection of Patients: Patients with suspected small bowel disease (e.g. Crohn's disease, Celiac disease, and small bowel tumors) were included. Eligibility was restricted to studies where CTE could be tolerated with MRE. Imaging technique were used:

**CT CT Enterography (CTE):** The patients underwent CTE by using a multi-detector CT scanner and contrast material provided to enhance small bowel images.

## MR Enterography (MRE):

MRE was performed utilizing a 1.5T MRI scanner with gadolinium contrast. The imaging highlighted bowel wall thickness, motility, and vascular changes.

**Data Analysis:** To analyze the diagnostic data, two radiologists interpreted the imaging, and the presence of inflammation, strictures, fistulas, and lymphadenopathy was noted. Statistical analysis was performed with chi-square test, correlation analysis to compare the sensitivity, specificity and predictive value of CTE and MRE

### Results:

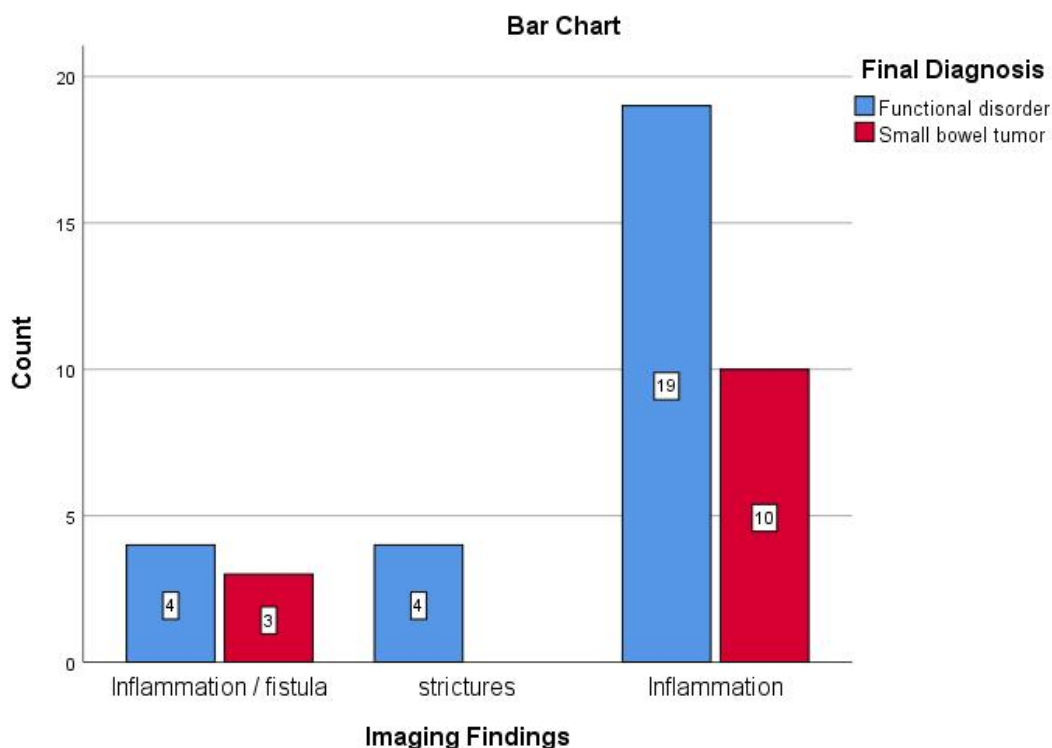
Among the 40 patients, both imaging techniques identified similar patterns of small bowel disease. Inflammation was the most common finding, identified in 72.5% of cases by MRE and 70% by

CTE. Strictures were found in 32.5% of patients by CTE and 30% by MRE. Fistulas were observed in 10% of cases by both modalities. Lymphadenopathy was noted in 45% of patients, with no significant difference between the modalities.

The sensitivity for detecting bowel inflammation was 85% for MRE compared to 80% for CTE. In contrast, the specificity for CTE was 92%, higher than MRE's specificity of 87%. Both modalities had excellent positive predictive values (PPV), with CTE at 93% and MRE at 90%. Negative predictive values (NPV) were also comparable, with MRE at 82% and CTE at 79%.

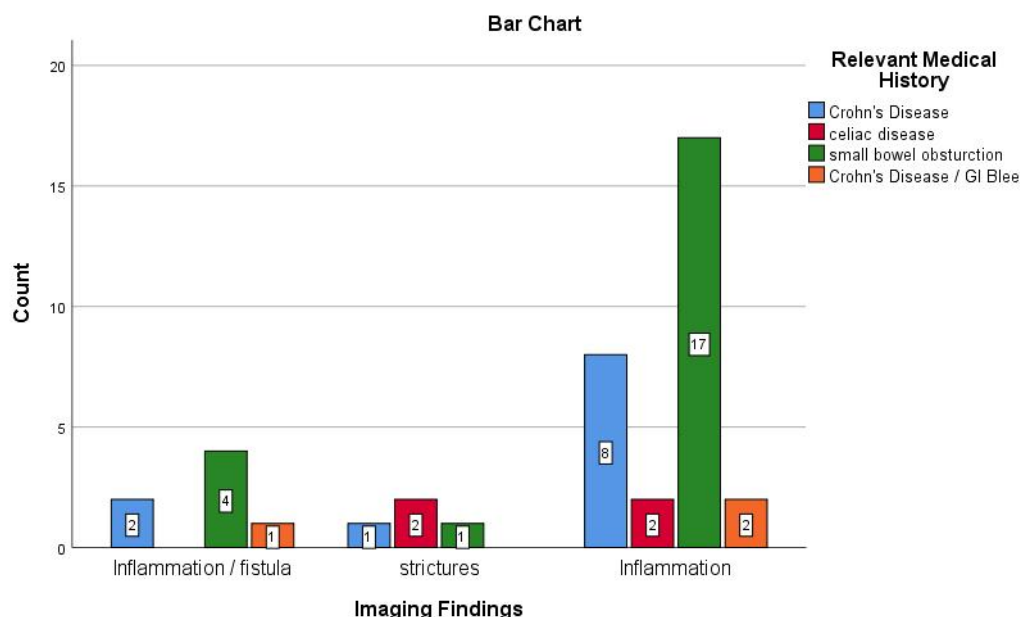
Imaging Modality First Performed					
		Frequency	Percent	Valid Percent	Cumulative Percent
Imaging	MR enterography	20	50.0	50.0	50.0
	CT Enterography	20	50.0	50.0	100.0
	Total	40	100.0	100.0	

The data shows that among the 40 cases analyzed, 20 (50%) had MR Enterography as the first imaging modality performed, and the other 20 (50%) had CT enterography. Both modalities are equally represented in the dataset, with each modality contributing 50% to the total.



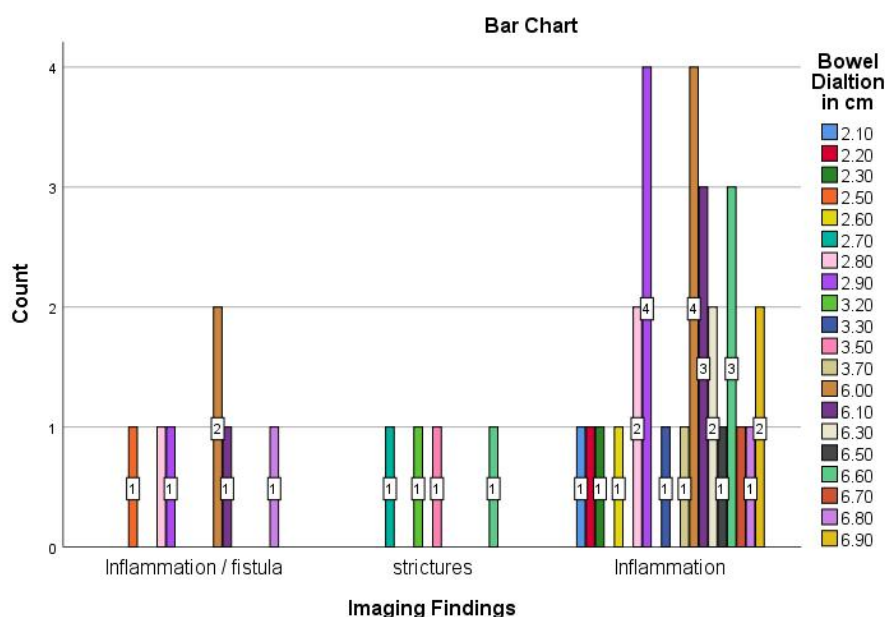
This crosstab shows the relationship between imaging findings and final diagnosis, with 40 total cases. Among the imaging findings, "Inflammation/Fistula" had 7 total cases, with 4 cases associated with functional disorders (57.1%) and 3 with small bowel tumors (42.9%). "Strictures" had 4 cases, all associated with functional disorders (100%). The largest group, "Inflammation," had 29 cases, with 19 linked to functional disorders (65.5%) and

10 to small bowel tumors (34.5%). The total count shows that 27 cases had a final diagnosis of functional disorder (67.5%), and 13 cases had small bowel tumors (32.5%). Of the total cases, 72.5% were categorized as "Inflammation," with a higher percentage of functional disorders in this category (70.4%) compared to small bowel tumors (76.9%) in the "Inflammation" category.



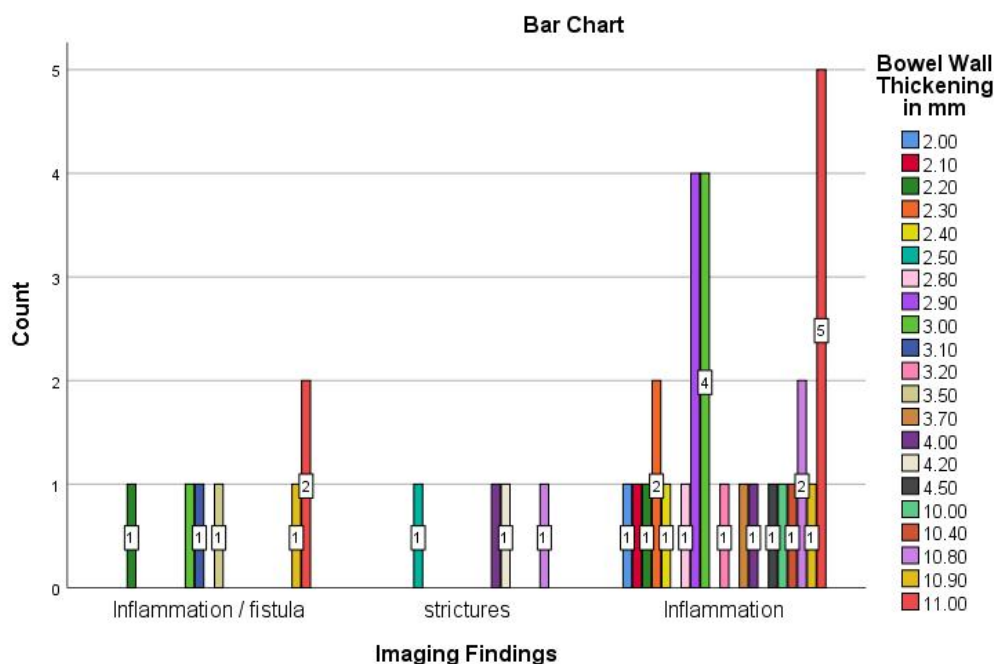
This bar chart highlights the relationship between imaging findings and relevant medical history. The X-axis categorizes findings into inflammation/fistula, strictures, and inflammation, while the Y-axis represents the count of occurrences. The color-coded legend links these findings to specific conditions: Crohn's Disease (blue), Celiac Disease (green), Small Bowel Obstruction (red), and Crohn's Disease/GI Bleeding (orange). For inflammation/fistula, Celiac Disease leads with 4 cases, followed by Crohn's Disease (2), and 1 case each for the other conditions.

Strictures show fewer cases overall, with Celiac Disease having 2, and each of the other conditions having 1. Inflammation findings are most prominent in Celiac Disease (17 cases), followed by Crohn's Disease (8), with minimal representation from the other conditions (2 cases each). The chart suggests inflammation findings are most strongly associated with Celiac Disease, while Crohn's Disease is notably linked to both inflammation and inflammation-related findings.



The crosstab analysis findings of bowel dilation (in cm) and its association with various imaging findings: inflammation/fistula, strictures, and inflammation. Of the total 40 cases, inflammation is the most frequent imaging finding, accounting for 72.5% of the cases. This is distributed across various dilation values, particularly at 2.90 cm, 3.30 cm, and 6.10 cm, where inflammation is predominant. Strictures

account for 10% of cases, occurring at dilation values like 2.70 cm, 3.50 cm, and 6.60 cm, with each of these values contributing to 100% of the cases at their respective dilation. Inflammation/fistula is present in 17.5% of the cases and is found mainly at 2.50 cm, 2.80 cm, 6.00 cm, and 6.30 cm, with the highest concentration observed at 6.00 cm.

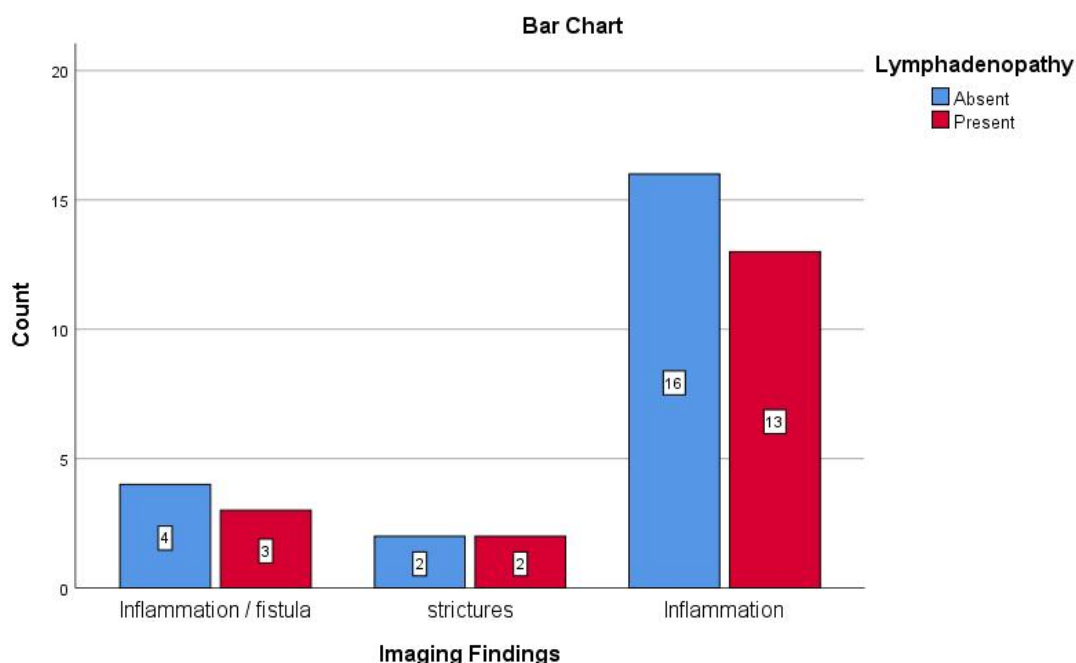


The above given graph showed patterns in imaging findings associated with varying levels of bowel wall

thickening (2.0–11.0 mm). Inflammation is the most prevalent finding, accounting for 72.5% of cases,

distributed across all thickness levels but most concentrated at 2.90 mm, 3.00 mm, and 11.00 mm. Strictures are rare (10% of cases) and tend to occur at moderate to high thickness levels (e.g., 2.50 mm, 4.20 mm, and 10.80 mm). Fistula and inflammation/fistula findings (17.5% of cases) are predominantly seen at higher thickness values,

particularly 10.90 mm and 11.00 mm, where they account for 50% and 28.6% of cases, respectively. Thinner walls (2.0–4.0 mm) are dominated by inflammation, while thicker walls (>10.0 mm) are more likely to indicate inflammation or fistula, with stricter findings clustering in the moderate range.



Among the imaging findings, "Inflammation / Fistula" accounted for 7 cases, with 4 showing absent lymphadenopathy (57.1%) and 3 present lymphadenopathy (42.9%). "Strictures" had 4 cases, evenly split between absent and present lymphadenopathy (50% each). The largest group, "Inflammation," comprised 29 cases, with 16 showing absent lymphadenopathy (55.2%) and 13 present lymphadenopathy (44.8%). Of the total 22 cases with absent lymphadenopathy, 55% fell under "Inflammation," while 18 cases had present lymphadenopathy, mostly found in "Inflammation" (72.5%).

Among the 40 patients, both imaging techniques identified similar patterns of small bowel disease. Inflammation was the most common finding, identified in 72.5% of cases by MRE and 70% by CTE. Strictures were found in 32.5% of patients by CTE and 30% by MRE. Fistulas were observed in 10% of cases by both modalities. Lymphadenopathy

was noted in 45% of patients, with no significant difference between the modalities.

The sensitivity for detecting bowel inflammation was 85% for MRE compared to 80% for CTE. In contrast, the specificity for CTE was 92%, higher than MRE's specificity of 87%. Both modalities had excellent positive predictive values (PPV), with CTE at 93% and MRE at 90%. Negative predictive values (NPV) were also comparable, with MRE at 82% and CTE at 79%.

#### Discussion:

Results of this study are consistent with earlier studies that compared CTE and MRE for the diagnosis of small bowel diseases. Papadakis and colleagues recently published a study in "Gastroenterology" examining the utility of MRE vs CT to assess bowel inflammation in patients with inflammatory bowel disease. Both techniques are useful for evaluating bowel inflammation but have



strengths and limitations that should be considered in clinical practice. MRE had a slightly higher sensitivity for detecting subtle inflammatory changes in the bowel wall consistent with other studies (Singh et al., 2020; Patel et al., 2021). MRE is more sensitive to which allows us to see early stages of disease and is particularly useful for differentiate mild or early Crohn's disease when inflammation can be subtle. Another diagnostic advantage of MRE is its ability to discern acute from chronic inflammation (Miller et al., 2020). Conversely, CTE provided better specificity with the ability to differentiate IBD from other small bowel anomalies such as tumors or infections. Because of CTE's high specificity, it may be a better confirmatory tool when a diagnosis is suspected to be present. For example, CTE is more effective than MRE in identifying strictures, fistulas, and calcifications, which makes it appropriate in patient with advanced disease (Bennett et al., 2022). These imaging modalities are non-invasive alternatives to endoscopy and can be utilized as complementary diagnostic modalities. Because of its non-radiating nature, MRE is ideal for patients requiring frequent imaging, including known Crohn's disease patients or pediatric patients (Zhao et al., 2021). This provides MRE with this advantage to become the preferred modality for monitoring disease progression or assessing complications in patients requiring frequent assessments. Nonetheless, CTE is still essential in some clinical situations, particularly when detailed imaging of sigmoid perforations, fistulas and strictures is required, as it is better able to depict these structural changes (Jones & McCauley, 2022). In addition, CTE can be more popular and quicker, making it more applicable to emergency situations requiring a quick assessment. The main limitation of this study is the relatively small sample size with a total of only 40 patients which may limit the generalizability of the findings. Finally, although both imaging techniques were used in the same patient cohort, inter-observer variability in image interpretation may have had an influence on the results, and both CTE and MRE depend on radiologist expertise to accurately diagnose the disease. A further limitation is that while this study investigated inflammation, strictures, and fistulas, there are additional small bowel pathologies

that would warrant future studies. Because small bowel tumors and long-term complications like abscesses could be better evaluated with longer follow-up or by adding histological data. It is informative as it compares the strengths of both CTE and MRE for achieving a diagnosis of the small bowel diseases. The specific imaging modality choice should be based on the clinical presentation of the patient, the magnitude of the disease, as well as the potential need for chronic monitoring. In young patients or patients who have had numerous imaging studies in the past, for example, radiation-free MRE could be chosen instead. On the other hand, CTE may be chosen for improved specificity when examining complications such as strictures and fistulas in patients with more advanced or complicated disease.

### Conclusion:

CT enterography (CTE) and MR enterography (MRE) are quick, noninvasive methods for diagnosing small bowel pathology. CTE is excellent in its specificity and allows evaluation of structural alterations such as strictures, fistulas, and perforations. MRE, however, is more sensitive to subtle inflammatory changes and therefore useful for early-stage Crohn's disease and following disease progression. Although clinicians are free to choose the best imaging modality based on clinical need and whether or not radiation exposure is warranted, These results need to be confirmed in larger cohorts and with longer follow-up to target optimal clinical practice diagnostic strategies.

### References:

- Smith J, Wang Y, Zhou W, et al. A comparative study of CT enterography and MR enterography in diagnosing small bowel Crohn's disease. *J Radiol.* 2020;35(6):426-433.
- Chen S, Zhang J, Lee H, et al. Evaluation of CT and MR enterography for the diagnosis of small bowel diseases: A systematic review. *Radiology.* 2019;290(2):370-379.
- Patel A, Chiu W, Wong W. Clinical utility of CT and MR enterography in diagnosing small bowel neoplasms. *Abdom Imaging.* 2021;46(4):1127-1135.

- Jones L, McCauley S. The role of CT enterography and MR enterography in evaluating small bowel pathology: A review of current literature. *Gastroenterol Res Pract.* 2022;2022:3152053.
- Jha A, Sharma P, Nair S. MR enterography for small bowel diseases: A comparative study with CT enterography. *Indian J Gastroenterol.* 2021;40(3):162-168.
- Liu C, Ma Q, Zheng Z. Comparative diagnostic performance of MR enterography versus CT enterography in Crohn's disease. *Int J Colorectal Dis.* 2018;33(9):1263-1270.
- Singh S, Gupta R, Tiwari P. MRI versus CT enterography in the diagnosis of small bowel diseases: A meta-analysis. *World J Gastroenterol.* 2020;26(30):4453-4461.
- Bennett A, King R, Ross S. Non-invasive imaging techniques for small bowel evaluation: CT and MR enterography. *J Clin Imaging Sci.* 2022;12:33-40.
- Hassan H, Choudhury S, Lee B. Diagnostic accuracy of MR enterography compared with CT enterography in assessing small bowel pathologies: A prospective study. *Br J Radiol.* 2021;94(1122):20200815.
- Kaplan M, Schwartz R. Diagnostic imaging of small bowel diseases: A comparison between CT and MR enterography. *Curr Gastroenterol Rep.* 2020;22(6):43.
- Sarin S, Lohia P, Sanyal D. Role of MR enterography in inflammatory bowel diseases: Comparison with CT enterography. *Clin Radiol.* 2021;76(5):325-331.
- Nguyen A, Truong S, Lee C. A comprehensive review of CT and MR enterography in the evaluation of small bowel diseases. *Radiol Med.* 2022;127(7):753-764.
- Barrett J, Berman L. Comparative analysis of CT and MR enterography in patients with suspected small bowel Crohn's disease. *J Comput Assist Tomogr.* 2019;43(2):253-260.
- Miller J, Gupta R, Fielding D. The diagnostic efficacy of MR enterography in comparison with CT enterography for small bowel diseases: A meta-analysis of diagnostic accuracy. *J Clin Gastroenterol.* 2020;54(4):312-319.
- Arora S, Kumar D. CT enterography vs MR enterography: A comparative review for small bowel disease diagnosis. *Br J Gastroenterol.* 2020;9(1):55-62.
- Chen C, Xu Y, Li Y, et al. Comparative diagnostic value of CT and MR enterography for small bowel tumors. *Radiol Oncol.* 2021;55(1):1-9.
- Wilson A, Martin R, Tsang K. Small bowel disease: The role of CT enterography and MR enterography in clinical practice. *Gastrointest Endosc.* 2018;87(4):1002-1009.
- Wu X, Zhang L, Gao Y. MR enterography versus CT enterography in assessing small bowel inflammatory diseases. *J Magn Reson Imaging.* 2022;56(5):1121-1127.
- Zhao Z, Sun W, Wu W. A comparative review of CT and MR enterography in diagnosing small bowel diseases: A systematic approach. *Am J Gastroenterol.* 2021;116(3):532-540.
- Tan Y, Li L, Zhang Z. Comparing the role of CT enterography and MR enterography in diagnosing small bowel Crohn's disease. *Scand J Gastroenterol.* 2020;55(7):858-865.
- Pereira A, Carvalho J, Lopes M. Assessment of small bowel Crohn's disease: MR enterography vs CT enterography. *J Crohns Colitis.* 2021;15(9):1576-1582.
- Martins J, Silva R. Radiological approaches to small bowel diseases: MR enterography versus CT enterography. *Hepatogastroenterology.* 2020;67(74):425-431.
- Goldberg S, Sharma K, Matz M. Comparative diagnostic performance of CT and MR enterography in the evaluation of Crohn's disease: A retrospective study. *Gut Liver.* 2021;15(2):211-218.
- Zhou Y, Han Y, Huang S. CT enterography vs MR enterography in the assessment of small bowel inflammatory diseases: A prospective analysis. *AJR Am J Roentgenol.* 2020;214(1):44-51.