

ULTRASONOGRAPHIC EVALUATION FOR DETECTION OF KIDNEY AND GALLBLADDER CALCULI

Rimsha^{*1}, Zumer², Asba³, Saima Bibi⁴, Noor Fatima⁵, Bisma Rehman⁶, Nuzhat Manzoor⁷, Ayesha Rashid⁸^{*1,2,3,4,5,6,7,8}Government College University of FaisalabadDOI: <https://doi.org/10.5281/zenodo.15726532>**Keywords**

Gallstone (GS), common Bile duct (CBD) and Common Bile Duct (CBD)

Article History

Received on 15 May 2025

Accepted on 15 June 2025

Published on 24 June 2025

Copyright @Author

Corresponding Author: *

Rimsha

Abstract

Mineral deposits accumulate and solidify within the kidney and gallbladder and form Renal and gallbladder calculi respectively. To enhance diagnostic results an early and precise diagnosis is essential. ultrasonography is used as a first-line imaging technique due to its real-time imaging, absence of ionizing radiation, and acceptability for follow-up imaging, especially in pregnancy and renal impairment.

Objective: The objective of this study is to assess the diagnostic accuracy, typical findings, and clinical importance of ultrasound for gallstones and renal stones

Material and method: For six months on 70 patients, ultrasonographic analytical scan was performed in DHQ hospital Faisalabad. It involved assessing suspected cholecystic and renal disease patients using real-time b-mode 3.5 MHz ultrasound scanners. High-resolution ultrasound scanners aid in locating the stone by identifying the sound shadow and focusing on the eco-organ.

RESULTS: After ultrasonography, a total of 1801 (7.31%) patients were diagnosed. The calculi usually measure about 6.3 mm across. The biggest calculi on record measured 22 mm, while the smallest were 0.9 mm. The 30% stones present in upper pole, 30% in lower pole and 40% in mid pole in kidney. Gallbladder calculi ranging from > 5mm to 10 mm are 54.3% and from 11 to >20mm are 46.7%.

Conclusion: Ultrasonography allows for safe and effective detection of stones in the urinary tract and GB. Its ability to find fine imaging procedures, differentiate calculi types and provide versatile information. By offering a non-invasive and comprehensive approach even in pregnancy, it facilitates earlier disease monitoring and reducing drastic effects of pathologies.

INTRODUCTION

Ultrasonography is a central component in the non-invasive diagnosis and management of gallbladder and renal calculi through the use of a safe, cost-saving, and widely available imaging modality. The objective of this study is to assess the diagnostic accuracy, typical findings, and clinical importance of ultrasound for gallstones and renal stones. Gallbladder calculi present as posterior acoustic shadowing with echogenic foci, usually with gallbladder wall thickening or pericholecystic fluid in more

complicated presentations like cholecystitis. Renal calculi, likewise, are seen as hyper echoic opacities with distal shadowing and, depending on the severity of obstruction, varying degrees of hydronephrosis. (1) Ultrasonography has good sensitivity for gallstones in symptomatic individuals but limited sensitivity for renal stones when small or ureteric calculi are present, where additional imaging like CT would be required. Even with such limitations, ultrasonography is used as a first-line imaging technique due to its real-time

imaging, absence of ionizing radiation, and acceptability for follow-up imaging, especially in pregnancy and renal impairment. When mineral deposits accumulate and solidify within the urinary tract or gallbladder, they form stones. Renal and gallbladder calculi are also known as nephrolithiasis and cholelithiasis independently, are generally encountered conditions in clinical practice and constitute a major public health concern encyclopedically. These stones, formed from the crystallization of colorful substances in the urinary or biliary tract, can affect in significant morbidity, including pain, inhibition, infection, and implicit damage to organ function if left undiagnosed or untreated.(2,3)

According to scales et al. (2012), roughly 12 of the population in developed countries will witness order calculi at some point in their continuance, while gallstones affect up to 20 of grown-ups, generally in middle-aged women (stinton and Shaffer 2012). The continuance frequency of renal stone is estimated to be 10 - 15 in males and 3 - 5 in ladies, while gallstones affect 10 - 20 of the adult population, with advanced circumstance in ladies and individualities over 40 times of age

In the evaluation of renal calculi, ultrasonography is able of detecting calculi within the renal parenchyma and collecting system, and relating complications, renal monuments generally appear as echogenic foci within the renal parenchyma or collecting system, frequently the original individual system accompanied by posterior aural shadowing. (4)

The capability to descry renal calculi varies among individualities, with studies indicating a perceptivity of around 54 and a particularity of 91. The discovery rate is affected by variables like gallstone size and placement is constantly .The stones set up in the upper and lower regions of the feathers pose distinct individual difficulties. Lower pole stones, especially those set up in the right order, can be guiding to fantasize because of their position that relies on the support of the bowel and the presence of gas. (5)

Again, stones located in the upper pole of the order are generally easier to pierce but may still be hidden in certain patient deconstructions, similar as hydronephrosis and fluid collections around the order. Still, its capability to decay ureteric calculi is not as high as that of reckoned tomography (CT). A relative study by Kanno et al. set up that the perceptivity and particularity of ultrasonography in detecting renal calculi were roughly 70 and 75 percent independently.(6)

When it comes to diagnosing gallbladder calculi, ultrasonography is the favored system. It has been proven to have a high position of delicacy, with perceptivity and particularity exceeding 95, in detecting gallstones. These monuments appear as echogenic foci with posterior aural shadowing within the gallbladder lumen. Gallstones are generally seen as bright spots on an ultrasound image that appear behind the liver and may move around when the patient changes positions. The delicacy of our system for detecting gallstones is reported to be around 96 for perceptivity and 90 for particularly. (7, 8)

MATERIAL AND METHOD:

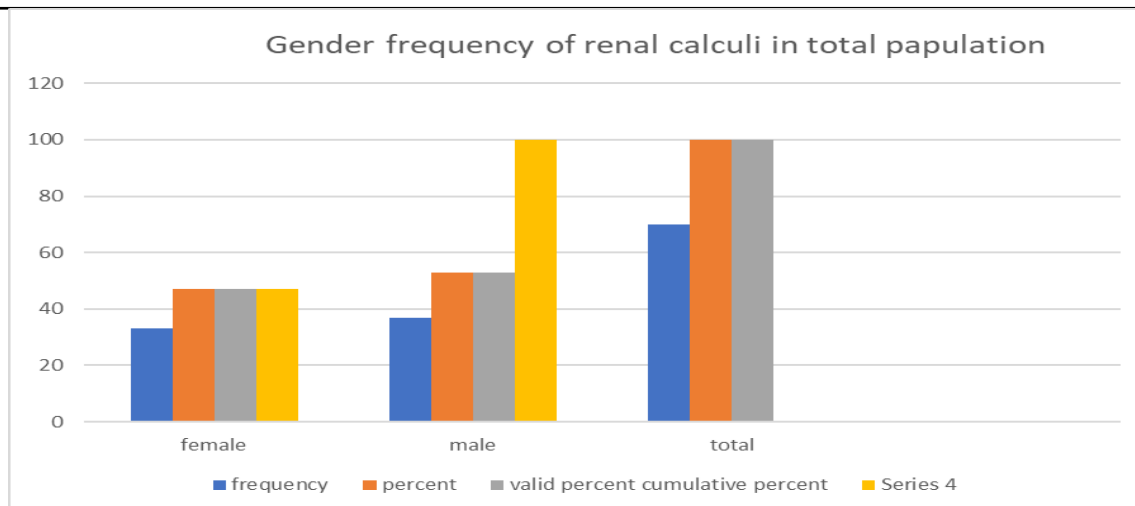
For six months on 70 patients, ultrasonographic analytical scan was performed in DHQ hospital Faisalabad. It involved assessing suspected cholecystic and renal disease patients using real-time b-mode 3.5 MHz ultrasound scanners. High-resolution ultrasound scanners aid in locating the stone by identifying the sound shadow and focusing on the eco-organ. It uses of high-frequency sound waves, typically ranging from 2 to 15 megahertz.

RESULTS:

In this study total 70 patients are present out of which 37 patients are males and 33 are females. After ultrasonography, a total of 1801 (7.31%) patients were diagnosed. The calculi usually measure about 6.3 mm across. The biggest calculi on record measured 22 mm, while the smallest were 0.9 mm.

Gender frequency

	Frequency	Percent	Valid Percent	Cumulative Percent
Valid female	33	47.1	47.1	47.1
Male	37	52.9	52.9	
Total	70	100.0	100.0	100.0



Graph: Gender frequency clustered column chart

DESCRIPTIVE STATISTICS

	N	Minimum	Maximum	Mean	Std.Deviation
Age valid	70	20	82	40.63	13.549
N(list wise)	70				

DESCRIPTIVE STATISTICS

	N	minimum	Maximum	Mean	Std.Deviation
STONE SIZE	64	2	38	5.05	6.808
Valid N Wise	64				

In this study the mean value of stone size is 5.05 and standard deviation of stone size is 6.808.

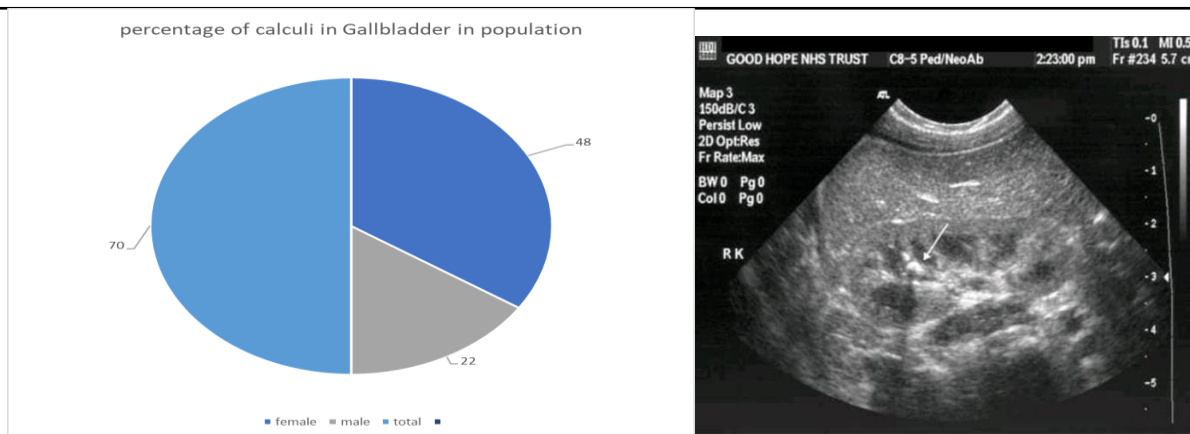
Frequency of stone location in kidney

	Frequency	percent	Valid percent	Cumulative Frequency
Upper pole	21	30	30	30
Lower pole	21	30	30	60
Midpole	28	40	40	100
Total	70	100	100	

This table shows that the frequency distribution of stone present in which location of kidney. The 30% stones present in upper pole, 30% in lower pole and 40% in mid pole

PERCENTAGE OF CALCULI IN POPULATION

Gender	No. of cases	Percentage
Female	33	68.6%
Male	37	31.4%
Total	70	100%

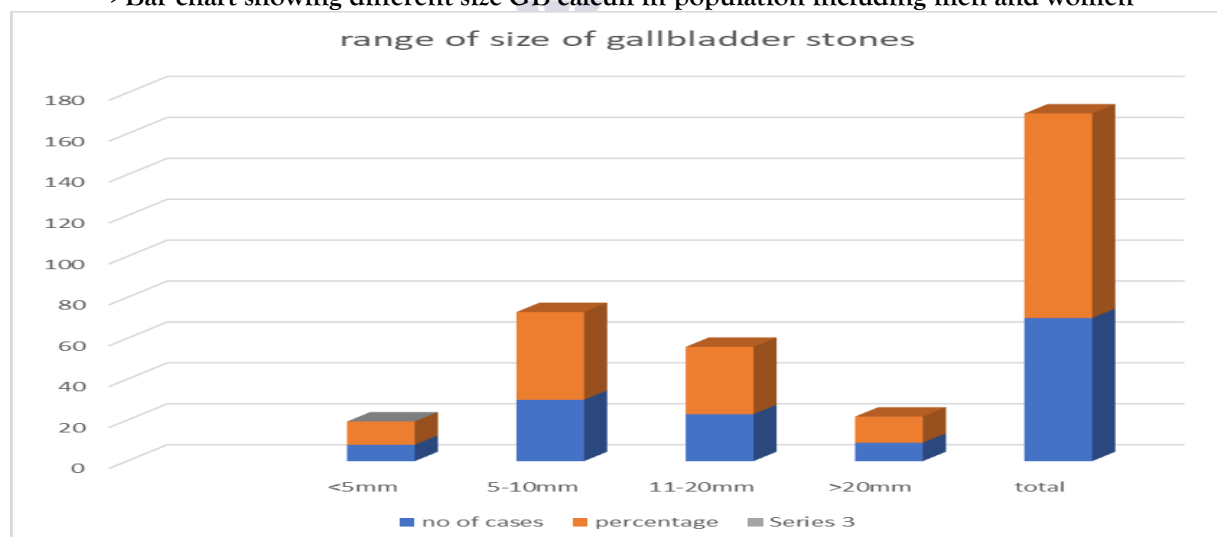


>Pie chart showing the GB calculi ratio in total population

TABLE 5.6: Different Size of calculi in population including Male and Female

Size of stone in GB	No. of cases	Percentage
<5mm	8	11.4%
5mm-10mm	30	42.9%
11-20mm	23	32.9%
>20mm	9	12.8%
Total	70	100%

>Bar chart showing different size GB calculi in population including men and women



DISCUSSION:

We examined 33 women and 37 men from the group based on analysis of medical records from 70 patients with renal and GB stones, seen on ultrasound. The stone was found on ultrasound for 70 patients, so a total of 64 have the stone, with just 6 patients showing no sign of it. The outcome harmonized with a study done by Terri J. Vrtiska in 1992 on prospectively detecting kidney stones through ultrasound and the

approach to managing patients with those stones. The findings reflect a comparison between KUB GB imaging and tomography of the KUB and GB area. The researchers studied the presence or absence of stones, together with their size, number per modality and where they were found. Renal stones were found by ultrasound in 77 out of the 83 patients. (9&10)

CONCLUSION:

Since small stones can have serious health effects, quickly finding and evaluating kidney and gallbladder calculi matters for the initial diagnosis and treatment. Today, especially ultrasonography allow for safe and effective detection of stones in the urinary tract. It works to relieve the symptoms of patients and also stops obstructing, infecting or damaging their organs. Continuing to develop diagnostic devices and medical procedures is necessary for improving patient results and reducing the likelihood that these conditions reoccur.

References:

- 1-Scales CD Jr, Smith AC, Hanley JM, Saigal CS. Prevalence of kidney stones in the United States. *Eur Urol*. 2012;62(1):160–165
- 2-Stinton LM, Shaffer EA. Epidemiology of gallbladder disease: cholelithiasis and cancer. *Gut Liver*. 2012;6(2):172–187.
- 3-Ahmad N, et al. Role of ultrasonography in the diagnosis of renal stones. *Pak J Med Sci*. 2015;31(5):1012–1016.
- 4-Demehri S, et al. Imaging of gallstones and complications: sonography, CT and MRI. *Curr Probl Diagn Radiol*. 2014;43(3):161–175.
- 5-Rahmouni A, Bargoin R, Herment A, Bargoin N, Vasile N. Color Doppler twinkling artifact in hyperechoic regions. *Radiology*. 1996;199(1):269–271
- 6-Türk C, Petřik A, Sarica K, et al. EAU Guidelines on Interventional Treatment for Urolithiasis. *Eur Urol*. 2016;69(3):475–482. doi:10.1016/j.eururo.2015.07.0
- 7-Gallbladder ultrasound | Radiology Reference Article - Radiopaedia. <https://radiopaedia.org/articles/gallbladder-ultrasound?lang=u>
- 8- Abu-Yousef MM, Mufid M, Cooper A, et al. The accuracy of sonography in gallstone detection: correlation with surgical findings. *AJR Am J Roentgenol*.
- 9-Ahmed, F., Askarpour, M.-R., Eslahi, A., Nikbakht, H.-A., Jafari, S.-H., Hassanpour, A., Makarem, A., Salama, H., & Ayoub, A. (2018). The role of ultrasonography in detecting urinary tract calculi: A comparison with non-contrast computed tomography. *Research and Reports in Urology*, 10, 199–206.
- 10-Anderson, J. C., & Harned, R. K. (1977). Gray scale ultrasonography of the gallbladder: An evaluation of accuracy and report of additional ultrasound signs. *American Journal of Roentgenology*, 129(6), 975–978.
- 11-Deitch, E. A. (1981). Utility and accuracy of ultrasonically measured gallbladder wall as a diagnostic criterion in biliary tract disease. *Digestive Diseases and Sciences*, 26(8), 686–693.
- 12-Fazel, M., Gubari, M. I. M., Yousefifard, M., & Hosseini, M. (2019). Ultrasonography in detection of renal calculi in children: A systematic review and meta-analysis. *Archives of Academic Emergency Medicine*, 7(1), e18.
- 13-Fowler, K. A., Locken, J. A., Duchesne, J. H., & Williamson, M. R. (1988). Renal calculi: Sensitivity for detection with US. *Radiology*, 167(1), 239–241.
- 14-Pathan, H., Shazlee, M. K., Iqbal, J., Ali, A. A., Hameed, K., & Ahmed, M. S. (2021). Diagnostic accuracy of renal calculi on ultrasonography taking computed tomography as gold standard. *International Journal of Community Medicine and Public Health*, 8(8), 3820–3823.
- 15-Van Ngoc, D., & Dinh Au, H. (2022). Evaluation of gallstone diagnosis and gallbladder contractility using ultrasound in patients treated with lithotripsy. *VNU Journal of Science: Medical and Pharmaceutical Sciences*, 38(2).
- 16-Watim, M. M., Pervaiz, M., Akhtar, N., Awan, M. F. A., Anwar, M., & Turabi, A. (2024). Sonographic determination of the association between grades of hydronephrosis and detection of kidney and ureteric calculi. *The Professional Medical Journal*, 31(01).

- 17- Morrison, J. C., et al. (2017). Pediatric urolithiasis patients and the use of ultrasound for diagnosis and management. Details about source missing in the image – consider adding journal or publisher].
- 18- Ganesan, V., et al. (2017). Sensitivity and specificity of ultrasound vs CT in detecting renal calculi. Exact journal or article title not provided – should be cited with complete source].
- 19-May, P. C., et al. (2016). Accuracy of S-mode and posterior acoustic shadow measurements using ultrasonography in diagnosing kidney stone size. Journal/publication not listed – cite properly if known].
- 20-Tzou, D. T., et al. (2020). Comparison of ultrasound-guided vs. fluoroscopy-guided PCNL in renal tract dilatation. Stata version 15.1 used for statistical analysis – ensure journal name is provided].
- 21- Maxwell, A. D., et al. (2019). Use of ultrasound lithotripsy in nephrolithiasis and transcutaneous delivery. Additional citation info required for formal reference].
- 22-Dai, J. C., et al. (2018). Study on posterior acoustic shadow width using ultrasound and CT in renal calculi.

